

*“ Evaluation of endovascular pedal arch
revascularization on clinical results and
tissue healing in diabetic foot patients
with lower limb ischemia ”*

Authors

Mohamed Mahmoud Ghweeba 1; Mayada Mahmoud Ghweeba 2

**¹Department of surgery, faculty of medicine, port-said university,
port-said, Egypt**

**²Lecturer of public health and preventive medicine, faculty of
medicine, Suez Canal University. Egypt**

Abstract

Background: The aim of the study was to evaluate the role of endovascular revascularization of the pedal vessels in diabetic patients with ischemic limbs on the rate of wound curing and healing and saving limbs.

Methods: prospective interventional study over a period of 30 months, 63 diabetic patients presented with critical limb ischemia (CLI), subjected to angiography showed pedal arch defect in three groups: complete pedal arch (CPA), incomplete pedal arch (IPA), and absent pedal arch (APA), and need revascularization. The rate and time of tissue healing and preservation of limb and avoid amputation were assessed using Kaplan–Meier curves between the different groups.

Results: all patients in the study were divided into three groups, CPA group 22 patients (34.9%), IPA 28 patients (44.5%), and APA group 13 patients (20.6%), with no difference statistically in age, gender and other chronic illness. The rate of healing and time consumed for curing in CPA patients was remarkably than other, 90% in CPA, 69% in IPA, and 54% in the APA group ($P=0.004$). The time consumed was (3.7 ± 2.3 , 4.2 ± 2.8 and 6.2 ± 3.4) respectively ($p=0.03$) for healing. While the limb preservation rate was magnificent in CPA patients (100%), (86%) in IPA, and (61.5%) in APA group; $P=0.01$). no need for minor surgical intervention was accomplished in 85%, 74.3%, and 46.7% respectively ($P=0.065$).

Conclusion: The endovascular intervention for dilatation of the pedal vessel has a great influence on saving the diabetic ischemic limbs, tissue preservation and improves their life.

Keywords: endovascular, critical limb ischemia, pedal arch, revascularization and amputation.

I-Scientific background:

Diabetes Mellitus (DM) considers the main risk factor of atherosclerosis in lower limb ischemia. ^(1, 2) By time, the rate of accidental diagnosis of DM elevated rapidly. So, the magnitude and direction of occurrence of critical ischemia special in older patients is propagated. ⁽³⁾ About 25% of peripheral arterial disease (PAD) within one year, the progress of the problem to a major amputation and the mortality due to comorbid conditions. ⁽⁴⁾

Revascularization is the cornerstone of limb ischemia with pedal arch occlusion for limb saving. The endovascular maneuver is the most recommended approach in multiple vascular units because of fewer complications than open surgery. ⁽⁵⁾

Most of patients presented with CLI are not candidate for surgical intervention because of advanced age, in addition to other comorbidities like, diabetes, smoking, hypertension as well as the nature of the pathological affection of atherosclerosis along the vessel wall and higher possibility of occurrence of restenosis and recurrent occlusion. Conversely, endovascular intervention with its updated specific tools, novel techniques, and advanced clinical experience is a new approach to establish adequate blood flow to the limb especially when threatened and jeopardized. It has become more recommended because of its less invasiveness and reasonable limb salvage rate compared with surgery. ⁽⁶⁾

The primary target of management of CLI is avoidance of limb amputation. Then, the secondary is achievement of complete wound healing in a shorter time. It was reported that variance between limb salvage and delay of recommended wound healing affected the quality of life and life style activities. So, it's very important to evaluate trophic ulcers in limb management after prevention of major amputation. ⁽⁷⁾

The concern of assessment of pedal arch in the presented patients with limb ischemia undergoing peripheral intervention will be established. ^(8,9)

The degree of atherosclerosis of the wall of the foot arch conceives a serious factor affecting the supply to ischemic areas of the foot. ⁽¹⁰⁾ Anterior and posterior circulation of the foot are connected each other by the pedal arch and the considered the main supply to the foot. The improvement rate of wound healing after revascularization is a good indicator of pedal arch patency. ^(11,12)

Methods:

A prospective interventional study done for recording 63 diabetic patients presented with CLI with pedal vessels occlusion, after exclusion of 9 patients during follow up post intervention, in El-Rahma hospital, Ataa specialized hospital and Omar Ibn El-Khattab specialized hospital in Port Said, Egypt. Patients included were Rutherford category 5 or 6 CLI and presented with infra-popliteal lesion with occlusion of pedal arch and revascularized beside the classical procedures of proximal tibial management with or without previous history of vascular intervention. All were consented and accepted participation in the study. This study was confirmed by faculty of medicine, port-said university Ethics Committee.

ERN :MED (4/4/2022) s.no(40) SPS/VSC_002

Patients with massive gangrene of soft tissue or those in septic shock and need urgent surgical amputation, totally occluded tibial segments that couldn't

be crossed by a wire and open, developing acute thrombosis, dissection, or perforation in infrapopliteal vessels and couldn't be managed prior to treatment of the arch were excluded from the study.

Data were gained from all patients included in the study, age, gender and occupation. Besides evaluation of related risk factors ⁽¹³⁾ included diabetes, ischemic heart disease (IHD), hypertension, hyperlipidemia, chronic renal disease, smoking and history of cerebrovascular stroke. Drug history was taken of receiving anticoagulant, clopidogrel, vasodilators and any allergies to contrast.

Clinical assessment of the patient's conditions as trophic lesions, ulcers, gangrene, Warmth of the skin, normal capillary refill time ~ less than 2 seconds) ⁽¹⁴⁾, assessment of bilateral peripheral Pulsations and bilateral ankle-brachial pressure index (ABPI), normal ABPI range of 1.00 - 1.30. ⁽¹⁵⁾

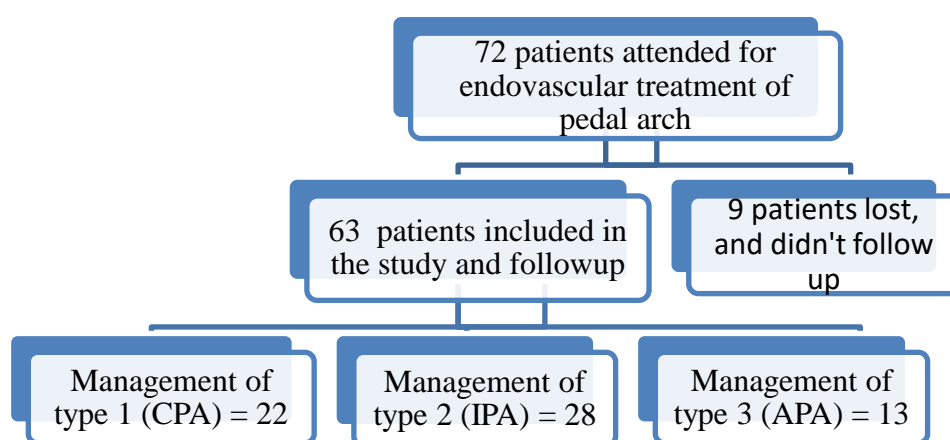


Fig.(1): patients flowchart of diabetic ischemic limbs

IV- Interventional procedure:

Pre-intervention drug taken were double treatment included acetyl salicylic acid 75 mg and clopidogrel 300 mg then a daily uninterrupted medication of clopidogrel 75 mg post the procedure for not less than 90 days. Regional xylocaine injection will be used in the ipsilateral femoral triangle for trans-femoral approach. A 5-French vascular introducer was inserted and about 70–100 U/kg of unfractionated heparin was given by direct Intra-arterial injection through the inserted sheath.

V-18 guidewire (Boston Scientific, Massachusetts, Boston, USA) was the choice to bypass used to the tibial lesion. Then, by crossing the lesion, dilatation of the vessel with 3 mm/dia. low profile balloons (sterling balloon; Boston Scientific) was inflated for 1–2 min. The loop wire technique will be done for the pedal-plantar arteries of affected foot to facilitate crossing the lesion. Indirect revascularization was performed as less recommended option if the direct procedure is not accessible. The process of revascularization of more than one vessel was the target to achieve maximum perfusion to the foot. In some cases to

overcome the spasm of distal vessels, Nitroglycerin was used in 100–200 µg to relieve it.

For the revascularization of the Pedal arch, used a 0.014-inch hydrophilic guidewire (PT2; Boston Scientific), and supported by a balloon (Amphirion Deep Balloon, Invatec; Medtronic, Minneapolis, Minnesota, USA). By success of bypass the wire to lesion of the occluded arch inflation of 2 mm balloon in its nominal pressure.

After completion angiography of the foot, patients were divided into three groups according to the pedal arch patency: complete pedal arch (CPA), incomplete pedal arch (IPA) and absent pedal arch (APA) group

The time passed for complete tissue healing and epithelialization after the procedure known as (time of healing). The follow-up of the cases included medical treatments and advanced wound care settings, and duplex ultrasound at discharge 1, 3, 6 and 12 months. (Fig. 4, 5)

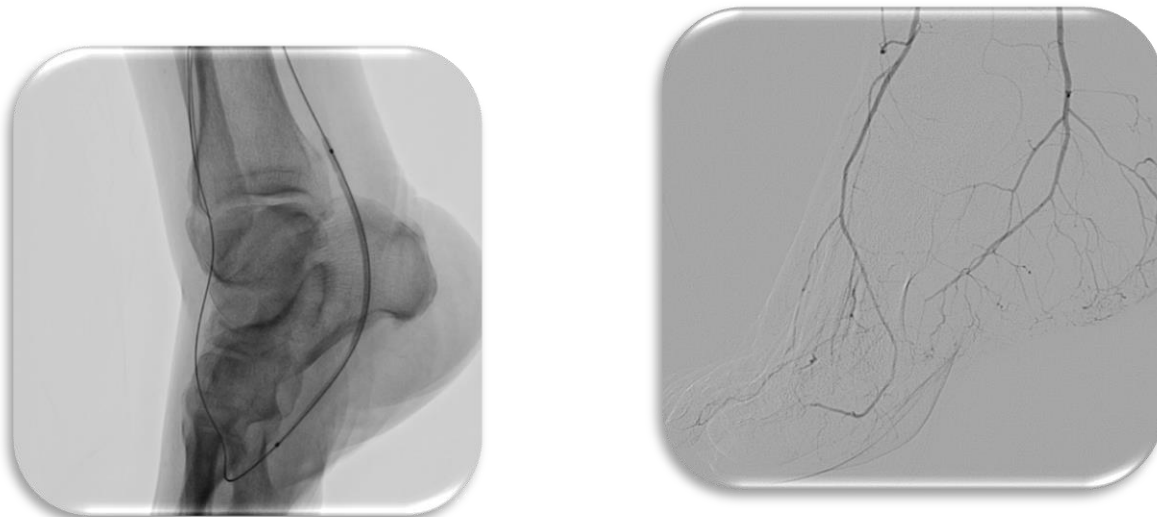
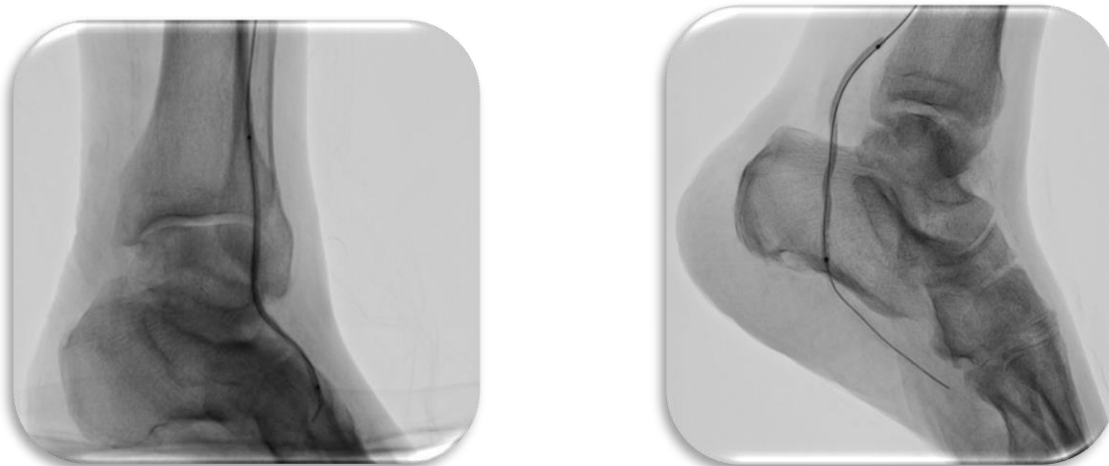


Fig. (1): complete pedal arch (CPA)



A **B**

Fig. (2): Incomplete pedal arch (IPA) with

A) Patent dorsalis pedis artery. **B)** Patent of the plantar artery.

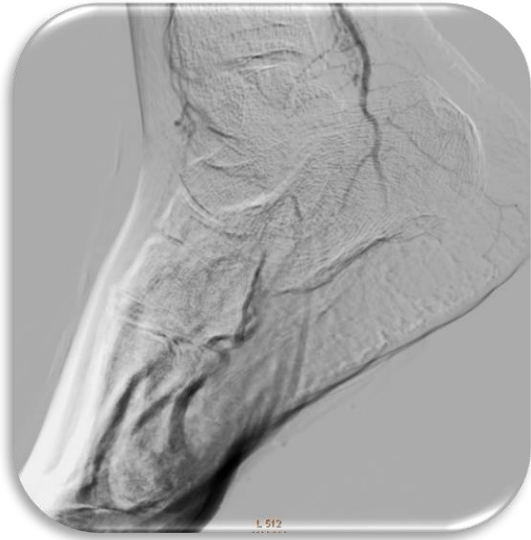

Fig. (3): Absent pedal arch (APA) (**A**)

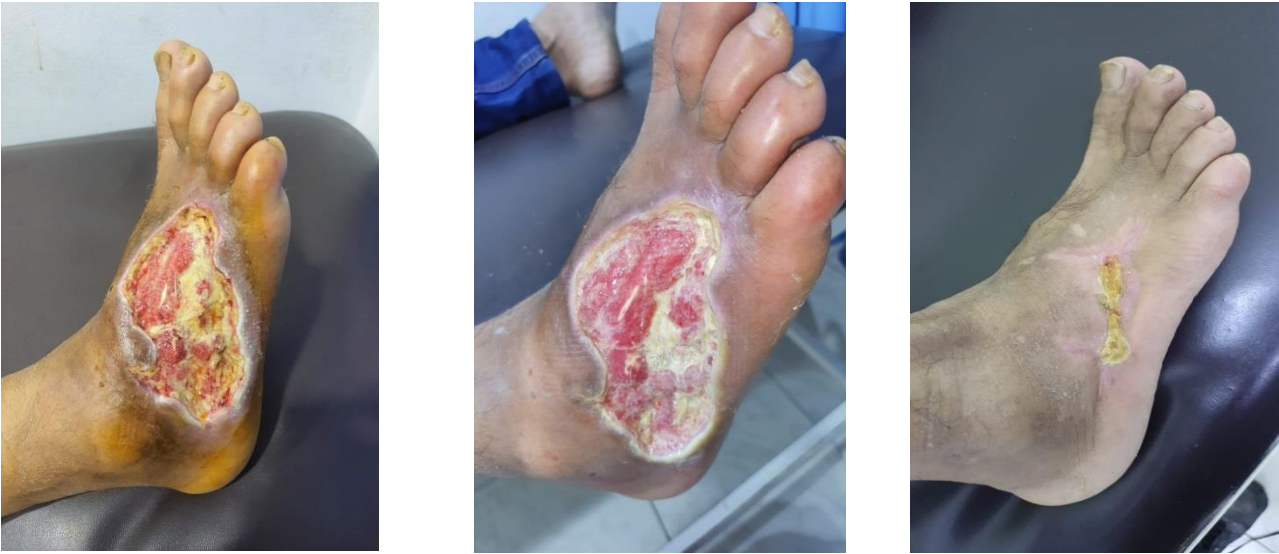
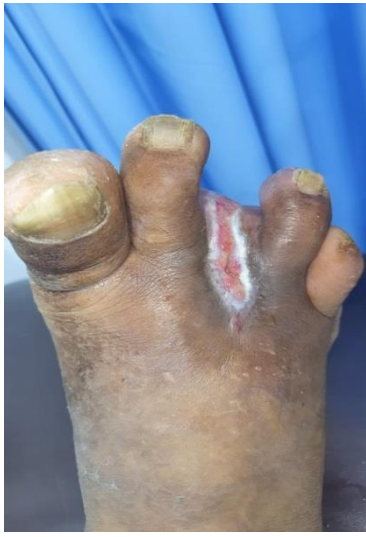
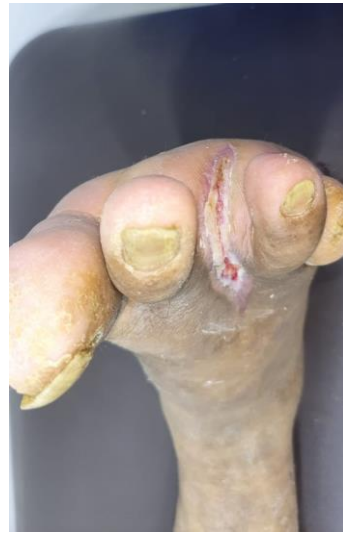Fig.(4): planter aspect RT foot ischemic ulcer.

- A) Necrotic ischemic ulcer, and need minimal debridement.
- B) Cleaned ulcer after debridement, for epithelialization.
- C) Complete healed ulcer after pedal arch revascularization (CPA).



(A)



(B)

Fig. (5): A) minor amputation of gangrenous RT 3rd toe, after pedal arch revascularization (IPA), start to heal. B) healed of the stump of amputated toe.

Data management:

The collected data from patients in the form of questionnaires and assessment and was processed by SPSS v.22 (IBM Corp. USA) computer package. The presentation of collected data was in the form of tables and figures using Microsoft word computer package in addition to Kaplan–Meier curves between the different groups. Q test and SD will be used for statistical evaluation. Results of significance hold a p -value ≤ 0.05 .

Results:

63 patients were included in the study and underwent pedal arch revascularization, and followed up for 12 month. Most of patients that included in the research were male (79%), with a mean age of 66.7 ± 9.7 years. All patients were diabetic and almost insulin dependent diabetes (93%). The other common risk factors were smoking; hypertension and hypercholesterolemia was (60%, 87% and 60% respectively) Table (1).

Risk factors	Type 1 (n=22)	Type 2 (n=28)	Type 3 (n=13)
Age >60 y	67 ± 9.9	66 ± 9.7	67 ± 9.4
Men	19 (38%)	22 (44%)	9 (18%)
Hypertension	18 (33%)	19 (34%)	18 (33%)
Type I diabetes	20 (34%)	17 (29%)	22 (37%)
Smoking	11 (29%)	10 (26%)	17 (45%)
Coronary disease	5 (23%)	8 (36%)	9 (41%)
Cardiac insufficiency	6 (32%)	7 (36%)	6 (32%)
Chronic renal disease	3 (28%)	4 (36%)	4 (36%)
Hypercholesterolemia	10 (26%)	13 (34%)	15 (40%)
Previous angioplasty	1 (20%)	1 (20%)	3 (60%)
Cerebrovascular disease	2 (22%)	3 (33%)	4 (45%)
Chronic obstructive pulmonary disease (COPD)	2 (25%)	3 (37.5%)	3 (37.5%)
Bed-ridden	0 (0.0%)	0 (0.0%)	2 (100%)

Table 1. All Patients' characters.

The revascularization of pedal arch was Type one (CPA) succeeded in 22 (35%) patients with 19 patients were men, the mean age was 67 ± 9.9 years, type two (IPA) in 28 (44.4%) patients with 22 patients were men, the mean age was 66 ± 9.7 years and type three (APA) in 13 (20.6%) patients with 9 patients were men and the mean age was 67 ± 9.4 years, with no considerable differences in patient baseline distinctive features between the three pedal arch groups.

In all groups, most of patients inserted had two distal artery run-offs (68%, 64% and 69% respectively). All the patients in the study had soft tissue loss; 40 patients (63.5%) were a Rutherford classification 5 and 23 patients (36.5%) were a Rutherford classification 6. The soft tissue affections were in the form of ulceration and gangrene. The tissue affection because of ischemia was mostly in toes in different groups (68.2%, 57.1% and 38.5% respectively) table (2).

Characters of lesions		Type 1 (n=22) (34.9%)	Type 2 (n=28) (44.5%)	Type 3 (n=13) (20.6%)	P value
Rutherford classification:					
5 (minor tissue loss)		15 (68.2%)	18 (64.3%)	7 (53.8%)	0.060
6 (major tissue loss)		7 (31.8%)	10 (35.7%)	6 (46.2%)	0.076
Form of Wound	Ulcer	13 (59.1%)	19 (67.9%)	8 (61.5%)	0.128
	Gangrene	9 (40.1%)	9 (32.1%)	5 (38.5%)	0.082
Site of tissue affection	Toes	15 (68.2%)	16 (57.1%)	5 (38.5%)	0.091
	Dorsal	4 (18.2%)	8 (28.6%)	3 (23.1%)	0.064
	Plantar	3 (13.6%)	4 (14.3%)	3 (23.1%)	0.149
	Heel	0	0	2 (15.3%)	0.183
Distal artery Run-off	One artery	4 (18.2%)	6 (21.4%)	2 (15.4%)	0.058
	Two artery	14 (36.6%)	18 (64.3%)	9 (69.2%)	0.098
	Three artery	3 (13.6%)	4 (14.3%)	2 (15.4%)	0.190

Table(2): characters of the lesions.

Patients in group one CPA intervention showed an exceptionally a shorter time of wound healing than needed in the other groups for healing. The healing rate and cured of wounds in type one (CPA) was 90%, in type two (IPA) was 69% and in type three (APA) was 54% ($P=0.004$). The time consumed for healing and improving was (3.7 ± 2.3 , 4.2 ± 2.8 and 6.2 ± 3.4) respectively ($p=0.03$) (Fig.: 6)

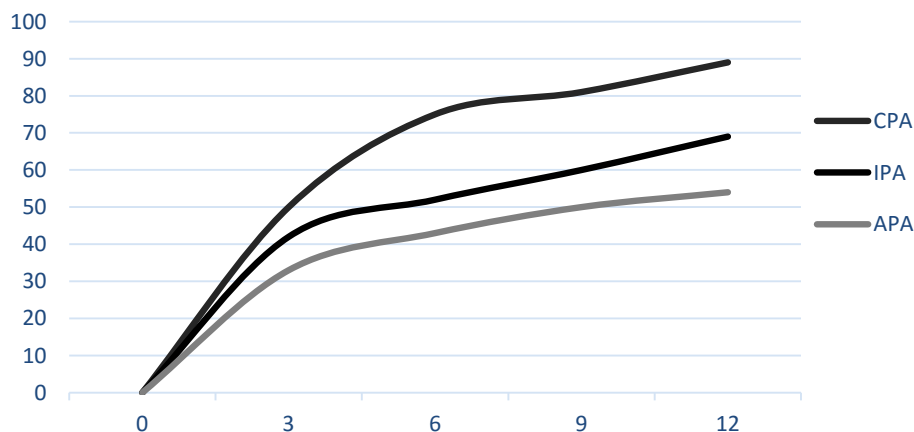


Fig.(6): The rate of healing

Saving limb and cured was significant ($P=0.01$); 100% in CPA patients, 86% in IPA, and 61.9% in APA (Fig. 5). The debridement and minor toes resection might be done to ischemic parts post revascularization in all involved patients in study. So, no minor interventions accomplished in 85%, 74.3% and 46.7% respectively ($P=0.065$) (Fig.: 7).

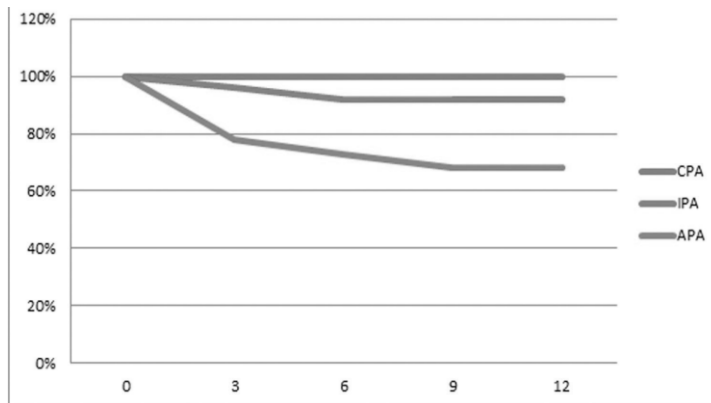


Fig. (7): rate of saving limb

Foot care:

The classical standard soft tissue care received to all patients with ischemic tissue affection, by minor debridement or resection of necrotic and gangrenous lesions.

In group one (CPA), 14 cases were treated by debridement, two patients had minor amputation, and no major amputation was recorded in this group. In group two (IPA), 15 cases were managed by minimal debridement, 11 patients needed minor amputation, and 2 done major surgical amputation. In the group three (APA), 3 cases with minimal debridement, 8 patients had minor amputation, and 3 cases had done major surgical amputation which required in sepsis and soft tissue necrosis or gangrene.

Concerning this study, access entrance site hematoma occurred in 5 (7.9%) patients and managed safely and resolved.

Discussion:

The prevalence of DM is spectacularly increasing. And this will explain an enormous rising rate of CLI incidence in elderly diabetic patients. ⁽¹⁶⁾

There is a great attentiveness of the associations between the risk factors of cardiovascular illness and vascular atherosclerosis of the lower limbs. A lot of reports presented diabetic ischemic patients “most distal, more effective” involving the foot and pedal vessels. ^(17, 18)

The significance of assessment of the pedal arch patency and its quality is important in keeping the revascularized tibial vessels patent. ^(4, 19) As connects the anterior and posterior flow and considered the main blood supply to the foot. So, intra-operative angiography of the pedal arch is decisive for successful of the procedure. ⁽²⁰⁾

There is more concentration of revascularization of the pedal vessels. Gloviczki *et al.* proved surgical bypass to the foot is safe, efficacious, and accessible maneuver for diabetic ischemic limbs before the decision of limb loss. ⁽²¹⁾ Furthermore, Davidson *et al.* confirmed the importance of patency of the pedal vessels for saving limb even in extensive tibial atherosclerosis. ⁽²²⁾

Rother *et al.* mentioned the thought of angiosome in endovascular management is a common strategy although the uncertainty of its benefit. ⁽²³⁾ This way is not usually accurate particularly in pedal arch lesion patients, as the circulation doesn't reach to the target tissue lesion in direct way and the blood flow through the recanalized vessels cannot reach the target area of the wound directly with normal blood supply. So, revision and revascularization of the pedal arch could be a limb saving and advantageous decision to improve healing of soft tissue. ⁽²⁴⁾

The target of management of any procedure for ischemic limb is to save it and avoid limb or tissue loss by reaching to complete healing for wounds or ulcers. This could reach by repeated debridement of the wounds, and improved life with less cost. Also, the delay in healing is a serious matter post intervention. Reed *et al.* mentioned in his thesis that, there was 20% variation between limb saving rate and wound restoration rate. So, still a respectable percent of patients complaining of uncured wounds although saving limbs done. ⁽²⁵⁾

Ischemic necrotic tissues in diabetic patients (especially uncontrolled and more serious with other risk factors) considered significant clinical problem and mostly reach to type of amputation. The basic endovascular maneuvers for ischemic limbs are inappropriate and the possibility of failure up to 20%. The more advanced techniques (retrograde approach, pedal arch loop maneuver or trans-collateral technique) are effective in ischemic limb saving and revascularization. ⁽²⁶⁾

Kawarada *et al.* had classified pedal arch lesions into three groups: group one patent both dorsal and lateral plantar vessels (CPA), group two had patent either the dorsal (group 2A) or lateral plantar (group 2B) artery(ICA), and type three occluded both dorsal and lateral plantar vessels(APA). ⁽²⁷⁾

Higashimori *et al.* mentioned that in patients presented with single tibial vessel runoff to the fore-foot, they need it was substantially important to revascularize the pedal arch to improve the circulation and perfusion and saving limb. ⁽²⁶⁾ As always of diabetic foot affection (necrosis and gangrene) are detected in the most distal part of foot. The blood supply to the foot by terminal vessels. So, the patency of the arch has great importance for limb saving. ⁽²⁸⁾

Acin *et al.* mentioned that the matter of angiosome considered no longer of efficacy compared with the direct blood circulation toward the target lesion, and depends on the rate of patency of the arterial blood supply to the target with collaterals. ⁽²⁹⁾ This manner was accepted with Higashimori *et al.* because of the distribution of angiosome could be changed or mixed in a different way by collaterals. ⁽²⁸⁾

The trial of more than one vessel revascularization was felicitous and judicious decision to achieve effective perfusion to the level of fore-foot. Even though this technique was approved by others, ⁽³¹⁾ other views mentioned that this technique has little clinical success and improvement. ⁽³⁰⁾

Nakama *et al.* had mentioned that in case of extensive foot infection require optimum revascularization and improved circulation for wound healing and limb saving. So, the pedal arch intervention will be beneficial in case of absence pedal flow. ⁽¹⁰⁾ Utsunomiya *et al.* mentioned that wound opacification (blushes) is also an indication for pedal arch revascularization depending on the angiographic distribution. ⁽³³⁾

Manzi et al. had mentioned that the technique of pedal plantar loop for patency of the vessel, and gives preferable outcomes and good perfusion and healing, using amphirion balloon. The prosperity of the procedure was accomplished in 49 patients (77.8%). But, Manzi technique mentioned that the success was 85%, and specified it as the diameter of the revascularized vessel less than 50% with blood flow.⁽¹³⁾

In 14 patients (22.2%) patients, the pedal arch was difficult to be revascularized and resulted in failure of blood supply to the foot. This was because the intractability of crossing of the lesion, perforation and managed by conservative with mild pressure or limitation of blood flows because of dissection and managed on table and followed up.

In the revascularized limbs in group one (CPA) were noticed a crucially higher rate of cured wound and less time consumed for healing was 90%, group two (IPA) 69% and in group three (APA) 54% ($p=0.004$). The time consumed for curing was (3.7 ± 2.3 , 4.2 ± 2.8 and 6.2 ± 3.4) respectively ($p=0.03$).

Rashid *et al.* mentioned that there was a notably variation in rate of healing and time consumed between the three groups.⁽¹¹⁾ But also, Nakama *et al.* and Troisi *et al.* had mentioned that, patients in group one and two are more advance in healing and saving limbs which assured the benefit of pedal vessel intervention.^(10, 12)

Kawarada *et al.* said that infected wounds in diabetic patients with pedal insult must be in mind as important reasons affecting tissue healing. By the end, it's a magnificent usefulness to present the importance of pedal arch endovascular revascularization to upgrade the outcomes of tissue healing, time consumed and preserving the diabetic ischemic limbs.⁽²⁵⁾

Conclusion

The endovascular dilatation of the pedal vessel has a great influence on saving the diabetic ischemic limbs, soft tissue preservation and improve the quality of life.

Cost support:

None.

Conflicts of interest

None.

References:

- 1- Dua A, Rothenberg KA, Lee JJ, Gologorsky R, Desai SS. Six-month freedom from amputation rates and quality of life following tibial and pedal endovascular revascularization for critical limb ischemia. *Vasc Endovasc Surg* 2019; 53:212–215.
- 2- Ramsey SD, Newton K, Blough D, McCulloch DK, Sandhu N, Reiber GE, et al. Incidence, outcomes, and cost of foot ulcers in patients with diabetes. *Diabetes Care*. 1999;22:382–387.
- 3- Singh N, Armstrong DG, Lipsky BA. Preventing foot ulcers in patients with diabetes. *JAMA*. 2005;293:217–228.
- 4- Boulton AJ, Vileikyte L, Ragnarson-Tennvall G, Apelqvist J. The global burden of diabetic foot disease. *Lancet*. 2005;366:1719–1724.
- 5- Shishehbor MH, White CJ, Gray BH, Menard MT, Lookstein R, Rosenfield K, et al. Critical limb ischemia: an expert statement. *J Am Coll Cardiol* 2016;68:2002e15.
- 6- Kobayashi N, Hirano K, Nakano M, Muramatsu T, Tsukahara R, Ito Y, et al. Predictors of non-healing in patients with critical limb ischemia and tissue loss following successful endovascular therapy. *Catheter Cardiovasc Interv* 2015; 85:850–858.
- 7- Shiraki T, Iida O, Takahara M, Soga Y, Yamauchi Y, Hirano K, et al. Predictors of delayed wound healing after endovascular therapy of isolated infrapopliteal lesions underlying critical limb ischemia in patients with high prevalence of diabetes mellitus and hemodialysis. *Eur J Vasc Endovasc Surg* 2015; 49:565–573.
- 8- O 'Mara CS, Flinn WR, Neiman HL, Bergan JJ, Yao JS. Correlation of foot arterial anatomy with early tibial bypass patency. *Surgery* 1981;89:743-52.
- 9- Lea Thomas M, Tanqueray AB, Burnand KG. Visualization of the plantar arch by aortography: technique and value. *Br J Radiol* 1988;61:469-72.
- 10- Nakama T, Watanabe N, Haraguchi T, Sakamoto H, Kamoi D, Tsubakimoto Y, et al. Clinical outcomes of pedal artery angioplasty for patients with ischemic wounds. *Cardiovasc Interv* 2017; 10:79–90.

- 11- Rashid H, Slim H, Zayed H, Huang DY, Wilkins CJ, Evans DR, et al. The impact of arterial pedal arch quality and angiosome revascularization on foot tissue loss healing and infrapopliteal bypass outcome. *J Vasc Surg* 2013;57:1219e26.
- 12- Troisi N, Turini F, Chisci E, Ercolini L, Frosini P, Lombardi R, et al. Pedal arch patency and not direct-angiosome revascularization predicts outcomes of endovascular interventions in diabetic patients with critical limb ischemia. *Int Angiol* 2017;36:438e44.
- 13- Manzi M, Fusaro M, Ceccacci T, Erente G, Dalla Paola L, Brocco E. Clinical results of below-the-knee intervention using pedal-plantar loop technique for the revascularization of foot arteries. *J Cardiovasc Surg* 2009;50:331-7.
- 14- Gandini R, Del Giudice C, Simonetti G. Pedal and plantar loop angioplasty: technique and results. *J Cardiovasc Surg* 2014;55:665-70.
- 15- Palena LM, Manzi M. Antegrade pedal approach for recanalizing occlusions in the opposing circulatory pathway of the foot when a retrograde puncture is not possible. *J Endovasc Ther* 2014;21:775-8.
- 16- Boulton AJ, Vileikyte L, Ragnarson-Tennvall G, Apelqvist J. The global burden of diabetic foot disease. *Lancet* 2005;366:1719-24.
- 17- Diehm N, Shang A, Silvestro A, Do DD, Dick F, Schmidli J, et al. Association of cardiovascular risk factors with pattern of lower limb atherosclerosis in 2659 patients undergoing angioplasty. *Eur J Vasc Endovasc Surg* 2006;31:59-63.
- 18- Chen Q, Smith CY, Bailey KR, Wennberg PW, Kullo IJ. Disease location is associated with survival in patients with peripheral arterial disease. *J Am Heart Assoc* 2013;2:e000304.
- 19- Lea Thomas M, Tanqueray AB, Burnand KG. Visualization of the plantar arch by aortography: technique and value. *Br J Radiol* 1988;61:469-72.
- 20- Manzi M, Cester G, Palena LM, Alek J, Candeo A, Ferraresi R. Vascular imaging of the foot: the first step toward endovascular recanalization. *Radiographics* 2011;31:1623-36.

- 21- Gloviczki P, Bower TC, Toomey BJ, Mendonca C, Nassens JM, Schabauer AM, et al. Microscope-aided pedal bypass is an affective and low-risk operation to salvage the ischemic foot. *Am J Surg* 1994;168:76-84.
- 22- Davidson JT 3rd, Callis JT. Arterial reconstruction of vessels in the foot and ankle. *Ann Surg* 1993;217:699-708; discussion 708-10.
- 23- Rother U, Krenz K, Lang W, Horch RE, Schmid A, Heinz M, et al. Immediate changes of angiosome perfusion during tibial angioplasty. *J Vasc Surg* 2017;65:422e30.
- 24- Spillerova K, Biancari F, Settembre N, Alback A, Venermo M. The prognostic significance of different definitions for angiosome-targeted lower limb revascularization. *Ann Vasc Surg* 2017;40:183e9.
- 25- Reed GW, Salehi N, Giglou PR, Kafa R, Malik U, Maier M, Shishehbor MH. Time to wound healing and major adverse limb events in patients with critical limb ischemia treated with endovascular revascularization. *Ann Vasc Surg* 2016; 36:190–198.
- 26- Palena LM, Brocco E, Manzi M. The clinical utility of below-the-ankle angioplasty using ‘transmetatarsal artery access’ in complex cases of CLI. *Catheter Cardiovasc Interv* 2014; 83:123–129.
- 27- Kawarada O, Fujihara M, Higashimori A, Yokoi Y, Honda Y, Fitzgerald PJ. Predictors of adverse clinical outcomes after successful infrapopliteal intervention. *Catheter Cardiovasc Interv* 2012; 80:861–871.
- 28- Higashimori A, Iida O, Yamauchi Y, Kawasaki D, Nakamura M, Soga Y, et al. outcomes of one straight-line flow with and without pedal arch in patients with critical limb ischemia. *Catheter Cardiovasc Interv* 2016; 87:129–133.
- 29- Kim S, Choi D, Shin S, Shin DH, Kim JS, Kim BK, et al. Dorsal-plantar loop technique using chronic total occlusion devices via anterior tibial artery. *Yonsei Med J* 2013; 54:534–537.
- 30- Acin F, Varela C, López de Maturana I, de Haro J, Bleda S, Rodriguez- Padilla J. Results of infrapopliteal endovascular procedures performed in diabetic patients with critical limb ischemia and tissue loss from the perspective of an angiosome-oriented revascularization strategy. *Int J Vasc Med* 2014;2014:270539.

- 31- Iida O, Soga Y, Yamauchi Y, Hirano K, Kawasaki D, Yamaoka T, et al. Clinical efficacy of endovascular therapy for patients with critical limb ischemia attributable to pure isolated infrapopliteal lesions. *J Vasc Surg* 2013; 57:974–981.
- 32- Kobayashi N, Hirano K, Nakano M, Muramatsu T, Tsukahara R, Ito Y, et al. Predictors of non-healing in patients with critical limb ischemia and tissue loss following successful endovascular therapy. *Catheter Cardiovasc Interv* 2015; 85:850–858.
- 33- Utsunomiya M, Nakamura M, Nakanishi M, Takagi T, Hara H, Onishi K, et al. Impact of wound blush as an angiographic end point of endovascular therapy for patients with critical limb ischemia. *J Vasc Surg*. 2012; 55:113–121.