

*“Which is worthy to be adopted, carotid stenting or carotid endarterectomy for treatment of symptomatic carotid artery stenosis?”*

**Authors**

**Amr Said Abu Elfadle** <sup>1</sup>; **Mohammed Elghareeb**<sup>2</sup>; **Mohamed Ghweeba** <sup>3</sup>; **Mohamad Abdelfaath Sakr**<sup>4</sup>; **Ahmed y Soliman**<sup>5</sup>

<sup>1</sup>Neurosurgery department, Faculty of medicine, Port said University, Egypt

<sup>2</sup>Neurosurgery Department, Faculty of medicine, South valley University, Qena, Egypt

<sup>3</sup>Department of surgery, faculty of medicine, port-said university, port-said, Egypt

<sup>4</sup>Neurology Department, Faculty of medicine, Misr University for science and technology

<sup>5</sup>Neurosurgery department, Faculty of medicine, Tanta University, Egypt

## **Abstract:**

**Background:** Carotid endarterectomy (CEA) has shown a valuable role in preventing stroke in symptomatic patients. However, it is limited by the presence of high-risk medical conditions. Alternatively, carotid artery stenting (CAS) has evolved as a less invasive therapeutic method.

**Objective:** This study aimed to compare between outcomes of artery stenting and carotid endarterectomy in asymptomatic carotid artery stenosis patients.

**Methods:** This retrospective cohort included 37 adult patients with symptomatic carotid artery stenosis. Patients were scheduled for either CAS (N=20) or CEA (N=17). The records were reviewed, and the patients' demographics, comorbidities, and clinical data were recorded. Carotid artery assessment via carotid duplex ultrasonography was also recorded. The primary endpoint of the study was the incidence of myocardial infarction or stroke within 30-days, and the incidence of death, stroke, or myocardial infarction at 1-year. The secondary endpoints included cranial nerve injury, restenosis, vessel maturation, intracranial haemorrhage, and any complications at the surgical site within one month after the procedures.

**Results:** Within 30 days of the procedures, the incidence of stroke or transient ischemic attack was 20.0% in the CAS group compared with 17.6% in the CEA group with no significant difference ( $p>0.999$ ). Myocardial infarction did not ensue in either group. No patients in the CAS group developed cranial nerve injury compared to two patients (11.8%) in the CEA group, with no significant difference ( $p=0.204$ ). The occurrence of local hematoma was lower in the CAS group (5.0%) than in the CEA group (29.4%), but it did not reach a significant level ( $p=0.075$ ). A 1-year follow-up, equal death, and stroke rates in the CAS and CEA groups were 10.0% versus 11.8% ( $p>0.999$ ).

**Conclusions:** Data from our present study indicate comparable death, stroke, or myocardial infarction rates within one month and at 1-year follow-up among patients who underwent CAS or CEA. Furthermore, there were no significant differences between CEA and CAS procedures regarding incidence rates of cranial nerve injury, local neck hematoma, or restenosis within one month of the procedures.

**Keywords:** carotid stenosis, endarterectomy, stenting, death, stroke, myocardial infarction.

## **Introduction**

Carotid artery stenosis denotes narrowing of one or both carotid arteries. It is closely related to carotid atherosclerosis. The process of atherosclerosis involves plaque formation with narrowing of the vascular lumen. The plaque may also rupture and give rise to a thrombus formation (1).

The progression of carotid atherosclerosis is slow, and carotid stenosis may remain asymptomatic in many cases (2). However, symptomatic patients may present with transient or permanent contralateral neurologic deficits such as weakness or numbness. Up to 20–30 % of ischemic strokes are attributed to carotid artery stenosis due to cerebral hypoperfusion or thromboembolism. Other ischemic manifestations in symptomatic patients include monocular visual loss, dysarthria, or vertigo (3).

For symptomatic stenosis that caused narrowing of greater than 50% of the vascular lumen, both surgical and medical interventions are indicated. The surgical intervention includes carotid endarterectomy (CEA) or carotid artery stenting (CAS) within two weeks of the symptoms. Medical therapy may include antiplatelet agents and statins and is mainly effective in preventing stroke (4).

Carotid endarterectomy showed a valuable role in preventing stroke in symptomatic patients, and it has been recommended as a standard treatment. However, it is limited by the presence of high-risk medical comorbidities that interfere with general anaesthesia. Alternatively, CAS has been evolved as a less invasive therapeutic modality (5).

A meta-analysis of randomized clinical trials concluded that death rate is comparable in both CAS and CEA; however, CAS carries a higher risk of stroke, and the risk of myocardial infarction is higher in CEA (6).

Considering the importance of reporting the outcomes of real-world practice of both CEA and CAS revascularization procedures, this study aimed to compare the outcomes of carotid artery stenting and carotid endarterectomy in symptomatic carotid artery stenosis patients.

## **Methods**

### **Ethical considerations**

Approval from Research Ethics Committee, Faculty of Medicine, Tanta University, Egypt was taken. We maintained the patients' confidentiality by keeping the records anonymous after assigning a code number to each patient

known only to the investigators.

### **Study design, settings, and date**

This prospective randomized control study was conducted at the Neurosurgery Departments of Tanta University Hospitals, Elsalam General Hospital, and South Valley University Hospitals, Egypt, between March 2018 and September 2021.

### **Inclusion criteria**

This study enrolled symptomatic carotid artery stenosis patients who were scheduled for either carotid artery stenting (CAS) or carotid endarterectomy (CEA).

### **Exclusion criteria**

#### ***For carotid endarterectomy***

We excluded patients with serious medical condition, heavy concentric calcification (3 mm in width by at least 2 orthogonal views), vascular tortuosity (2 bend point that exceeded 90° within 5 cm of the lesion), high carotid bifurcation, intraluminal thrombus, large or immobile neck, previous neck irradiation, prior neck operation, and contralateral carotid occlusion. Patients presented with a major stroke or had a history of major devastating stroke with minimal recovery were excluded. Also, patients with significant disturbance of consciousness were also excluded.

#### ***For carotid artery stenting***

We excluded patients with a fully collapsed internal carotid artery (ICA) distal to the near-occlusion.

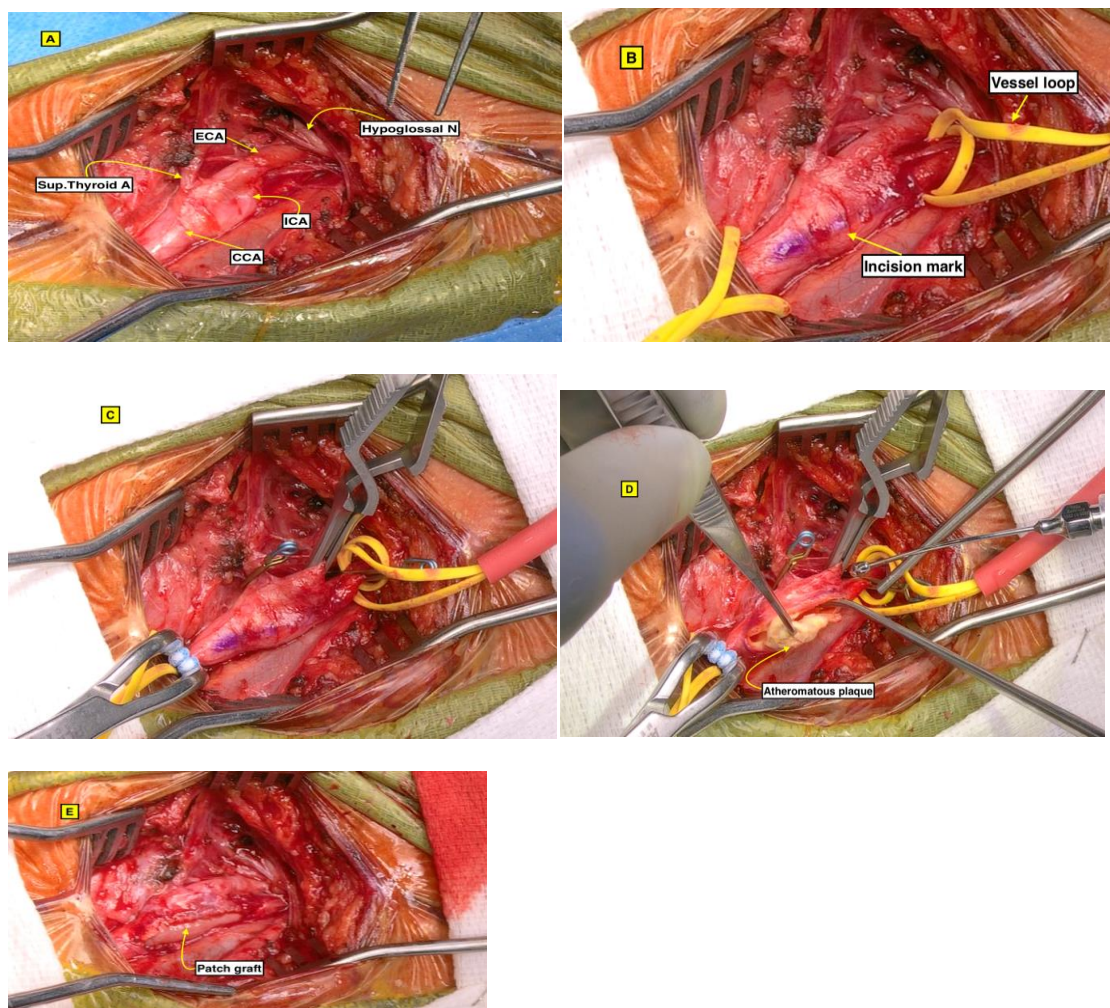
### **Data collection**

The records were reviewed and the data including age, gender, history of neck operation, congenital cervical deformity, previous angioplasty, associated comorbidities including diabetes mellitus, hypertension, renal insufficiency, coronary artery disease, hyperlipidaemia, besides smoking were collected. In addition, preoperative clinical manifestations such as stroke, transient ischemic attack, amaurosis fugax, vertigo, syncope were recorded. Neuroimaging using computed tomography (CT) scan, and carotid artery assessment via carotid duplex ultrasonography were also recorded.

## *Technique for carotid endarterectomy*

In supine position, the head is placed on a firm holder with extended neck and turned away from the side surgery, Incision was made alongside the medial aspect of the sternocleidomastoid muscle dissecting deeply to the carotid sheath.

Careful incision of the sheath, exposure of carotid arteries then clamping of internal carotid artery (ICA) followed by common carotid artery (CCA) and lastly external carotid artery (ECA). Longitudinal opening of internal carotid artery and proceeding beyond both ends of the plaque were done followed by careful removal of the plaque. We prefer closure of the arteriotomy with a patch graft to increase the caliber of the vessel and reduce the risk of restenosis. Lastly, we release the clamps starting with that of ECA followed by CCA and lastly the ICA. the importance of this order of de clamping is to force any embolus or thrombus if present into the ECA Satisfactory blood flow is to be confirmed with angiography or ultrasound Doppler. Fig (1)





## **Fig 1: 69 years old male with left sided high grade carotid stenosis:**

**A:** carotid artery dissection.

**B:** a vessel loop is placed around CCA and ICA for proximal control.

**C:** Order of vessel occlusion as follows: first ICA followed by CCA and lastly ECA and the goal of

this order is to force any embolus/thrombus if present into ECA.

**D:** Removal of the plaque.

**E:** Arteriotomy closure with patch graft to increase the caliber of the vessel and reduce the risk of restenosis

### ***Technique for carotid artery stenting***

Dual-antiplatelet therapy (DAPT) with aspirin (81-325 mg/day) plus clopidogrel (75 mg/day) should be started before the procedure and continued for at least one month. [17] Ticlopidine (250 mg twice/day) was recommended for patients who cannot tolerate clopidogrel. Statin therapy before intervention may reduce procedural complications. [18]. Under conscious sedation and local anaesthesia, the intervention begins with diagnostic cervical carotid and cerebral angiograms to assess the carotid stenosis and vascular access route for any severe tortuosity and for tandem stenoses, whether extracranially or intracranially, then we calculate the diameter of the ICA at the intended landing zone of the embolic protection device and the diameters of the native ICA and distal CCA are also measured, these dimensions help us in choosing the stent size, balloons, and embolic protection device.

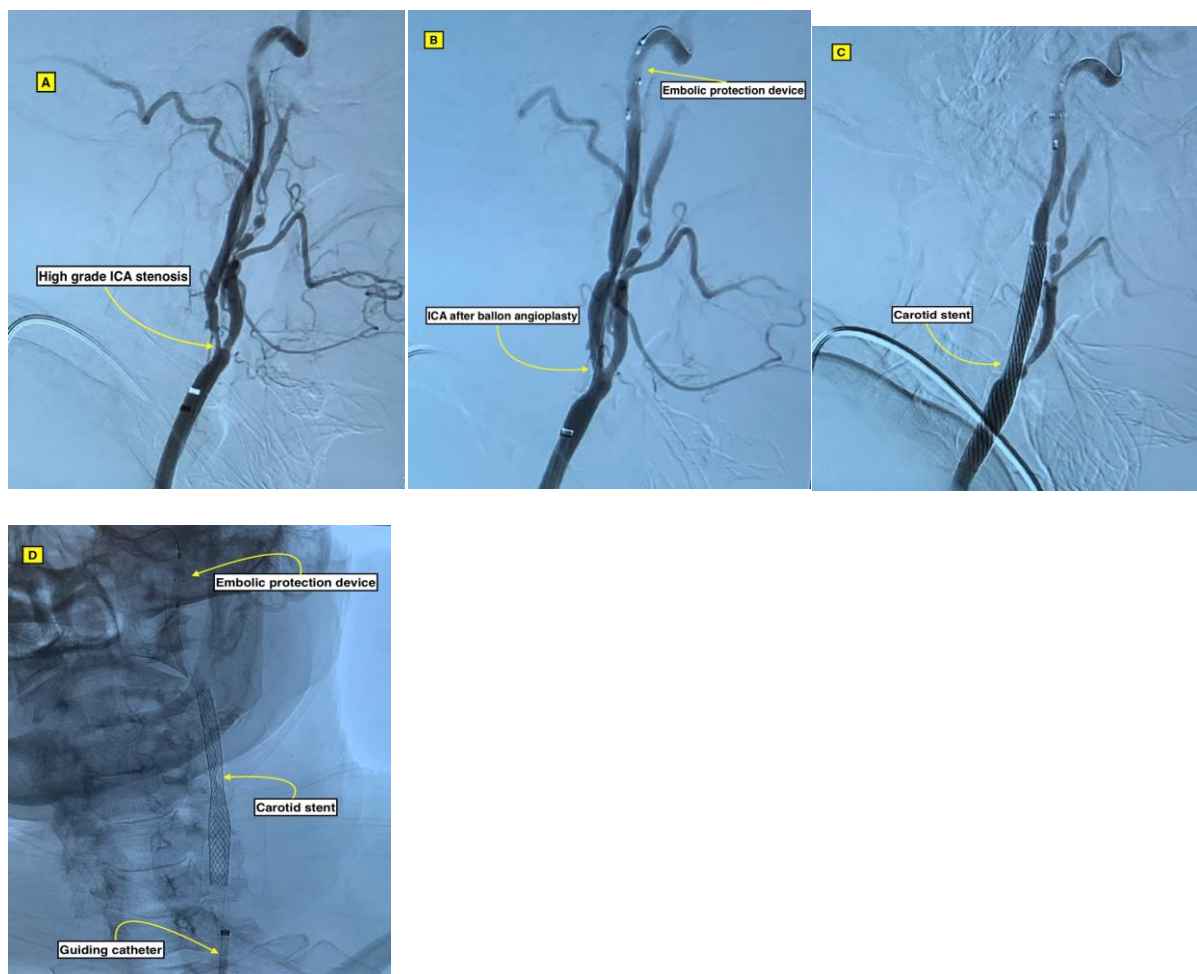
After completion of the angiography, the diagnostic catheter and groin sheath are exchanged over a stiff 0.035-inch wire for a 6 Fr, 90 cm long introducer. The exchange-length stiff wire is positioned in the distal external carotid artery branches to achieve stability during the exchange maneuver. The 6 Fr introducer is positioned in the distal part of the common carotid artery.

The patient is then given intravenous heparin (typically, 50–70 units/kg) in order to achieve an activated coagulation time (ACT) between 250 and 350 seconds.

The embolic protection device (The Spider™ Embolic Protection Device) is advanced distally and deployed in a straight portion of distal cervical ICA. We

perform angioplasty with Sterling monorail balloon dilatation catheter followed by stent deployment using Carotid wall stent or [Protégé Self-expanding Carotid Stent](#).

Post stenting angioplasty was performed if still residual stenosis exists post stent insertion, it would appear as waist of an hourglass on fluoro- scopic images Fig (2).



**Fig 2: 70 years old female patient with left sided high-grade carotid artery stenosis:**

**A:** 84% carotid artery stenosis according to NASCET criteria

**B:** Balloon angioplasty with 4 by 40mm Aviator balloon after deployment of embolic protection device (6 mm Angio guard).

**C:** Carotid stenting using 10 by 31 mm carotid wall stent.

**D:** un subtracted AP image demonstrates: Embolic protection device, carotid stent and

guiding catheter.

**Postoperative care and follow-up**

Patients were admitted with meticulous follow-up hourly for 24 hours and discharged 2 days later. Patients were followed-up with regular duplex ultrasonography as well as clinically for one year.

**Outcomes**

The primary endpoint of the study was the incidence of each of stroke or myocardial infarction within 30 days after the procedures, and the incidence of each of death, stroke, or myocardial infarction at 1-year following the procedures. The secondary endpoints included cranial-nerve injury, restenosis, vessel maturation, intracranial haemorrhage and any complications at the surgical site or the vascular access site within 30 days after the procedures.

Stroke was assessed by using National Institutes of Health Stroke Scale (NIHSS) (7) and the Transient Ischemic Attack (TIA)–Stroke Questionnaire (8). Measuring cardiac enzyme levels and electrocardiography assess myocardial infarction during follow-up period. Regular assessment of carotid condition by ultrasonography was performed.

**Statistical analysis**

The information obtained was tabulated and analysed by using SPSS Ver 22 (IBM Corp. USA). Data obtained were represented as frequencies and percentages and associations between categorical variables were analysed using



Pearson's Chi-square and Fisher's Exact tests as appropriate. Numerical variables were checked for distribution by the Shapiro Wilk test. Normally distributed variables were presented as mean  $\pm$ SD, and differences between the studied groups were tested by Independent T-test. A p-value of  $<0.05$  was considered statistically significant.

## Results

This study included 37 adult symptomatic carotid artery stenosis patients who were scheduled for either CAS (N=20), or CEA (N=17). The mean age of the patients in both groups were  $63\pm 9.7$  and  $65\pm 10.3$  years, respectively with no significant difference ( $p=0.547$ ). Males constituted 75% of the CAS group and 82.4% of the CEA group with no significant difference ( $p=0.701$ ). Both CAS and CEA groups showed comparable comorbidity characteristics with no significant differences ( $p>0.05$ ) that included diabetes mellitus (60.0% versus 64.7%), hypertension (85.0% versus 58.8%), renal insufficiency (0.0% versus 11.8%), hyperlipidaemia (55.0% versus 82.4%), and smoking (40.0% versus 70.6%) (Table 1).

**Table (1): Baseline demographic characteristics and comorbidities of the studied groups**

	Carotid artery stenting		Carotid endarterectomy		P-value
	N=20		N=17		
Age (year), Mean $\pm$ SD	63 $\pm$ 9.7		65 $\pm$ 10.3		0.547
Sex (Male)	15	75.0%	14	82.4%	0.701
Diabetes mellitus	12	60.0%	11	64.7%	0.769
Hypertension	17	85.0%	10	58.8%	0.136
Renal insufficiency	0	0.0%	2	11.8%	0.204
Coronary artery disease	14	70.0%	5	29.4%	0.014*
Hyperlipidaemia	11	55.0%	14	82.4%	0.077
Smoking	8	40.0%	12	70.6%	0.063

\*Significant at  $p<0.05$

The severity of carotid stenosis in the CAS and CEA groups varied between 50% and 70% (25.0% versus 35.3%, respectively) or more than 70% (75.0% versus 64.7%, respectively). There was a significant difference between CAS and CEA groups regarding the presence of coronary artery disease (70.0% versus 29.4%, respectively,  $p=0.014$ ). Furthermore, history of stroke, TIA, amaurosis fugax, vertigo, syncope, neck operation, congenital cervical deformity, and previous angioplasty showed similar frequencies in both CAS and CEA groups with no significant differences ( $p>0.05$ ) (Table 2).

**Table (2): Severity of the carotid stenosis and the preoperative clinical manifestations of the studied patients**

	Carotid artery stenting		Carotid endarterectomy		P-value
	N=20		N=17		
Stroke	7	35.0%	8	47.1%	0.457
Transient ischemic attack	5	25.0%	6	35.3%	0.495
Amaurosis fugax	3	15.0%	2	11.8%	>0.999
Vertigo	3	15.0%	5	29.4%	0.428
Syncope	3	15.0%	4	23.5%	0.680
Carotid stenosis 50-70%	5	25.0%	6	35.3%	0.495
Carotid stenosis >70%	15	75.0%	11	64.7%	0.495
History of neck operation	2	10.0%	0	0.0%	0.489
Congenital cervical deformity	1	5.0%	0	0.0%	>0.999
Previous angioplasty	3	15.0%	2	11.8%	>0.999

\*Significant at  $p<0.05$

Within 30-days of the procedures, the incidence of stroke or TIA was 20.0% in the CAS group compared with 17.6% in the CEA group with no significant difference ( $p>0.999$ ). Myocardial infarction did not ensue in either group. None of the patients in the CAS group developed cranial nerve injury, while two patients (11.8%) in the CEA group developed it, with no significant difference ( $p=0.204$ ). Occurrence of local hematoma was less in the CAS group (5.0%) than in the CEA group (29.4%), but it did not reach a significant level ( $p=0.075$ ). One patient in the CAS group developed bradycardia and hypotension, but none of the patients in the CEA group showed them ( $p=>0.999$ ). Restenosis was detected in four patients (20.0%) belonging to the CAS group and two patients (11.8%) in the CEA group, with no significant difference ( $p=0.667$ ). The incidence of vessel maturation was 16 out of 20 patients in the CAS group (80%), and it was observed in all the 17 patients in the CEA group (100%), with no significant difference ( $p=0.109$ ). Regarding intracranial haemorrhage, we did not observe it in either group (Table 3).

**Table (3): Outcomes of carotid artery stenting and carotid endarterectomy within 30 days of the procedures**

	Carotid artery stenting N=20		Carotid endarterectomy N=17		P-value
	N	%	N	%	
Stroke/transient ischemic attack	4	20.0%	3	17.6%	>0.999
Myocardial infarction	0	0.0%	0	0.0%	NA
Cranial nerve injury	0	0.0%	2	11.8%	0.204
Local hematoma	1	5.0%	5	29.4%	0.075
Bradycardia/hypotension	1	5.0%	0	0.0%	>0.999
Intracranial hemorrhage	0	0.0%	0	0.0%	NA
Restenosis	4	20.0%	2	11.8%	0.667
Vessel maturation	16	80.0%	17	100.0%	0.109

NA: not applicable

Comparison of the outcomes between both groups at 1-year follow-up revealed equal death rates as well as occurrence of stroke in the CAS and CEA groups (10.0% versus 11.8%, respectively;  $p>0.999$ ). Though the incidence of myocardial infarction was more in the CAS than in the CEA groups (20.0% versus 0.0%), this difference had no statistical significance ( $p=0.109$ ) (Table 4).

**Table (4): Outcomes of carotid artery stenting and carotid endarterectomy at 1-year following the procedures**

	Carotid artery stenting		Carotid endarterectomy		P-value
	N=20		N=17		
	N	%	N	%	
Death	2	10.0%	2	11.8%	>0.999
Stroke	2	10.0%	2	11.8%	>0.999
Myocardial infarction	4	20.0%	0	0.0%	0.109

## Discussion

This study revealed a comparable within 30 days periprocedural stroke and myocardial infarction rates among the CAS and the CEA groups with no significant differences. Furthermore, analysis of death, stroke, and myocardial infarction rates at 1-year following both procedures indicated equal distribution among both groups. We also could not detect a significant difference between CAS and CEA regarding the risk of bradycardia and hypotension, intracranial haemorrhage, cranial nerve injury, or restenosis within 30 days of the procedures. Thus, in patients with moderate or severe symptomatic carotid stenosis, CAS could be considered an equivalent choice to CEA.

In the present study, stroke or TIA incidence was 20% in CAS compared to 17.6% in CEA during the 30-days periprocedural period, while it was 10% versus 11.8% at 1-year, with no significant differences. No patients in either group developed myocardial infarction during the 30-days periprocedural period, but at 1-year, the rate of myocardial infarction was higher in CAS than CEA (20% versus 0%,  $p=0.109$ ) but it did not reach a significant level. Comparison of the death rate at 1-year revealed comparable findings of 10% and 11.8%, respectively with no significant differences. Our findings coincide with Tas et al (9) who reported a retrospective single centre experience of CAS and CEA. They

found non-significant differences in the 30-days and 1-year outcomes that included transient ischemic attacks, stroke, myocardial infarction, or all-cause mortality. Furthermore, long-term risk of fatal or disabling stroke at 1-year, 5-years, or final follow-up were similar in CAS and CEA treatment modalities for symptomatic carotid stenosis with no significant differences (10). Furthermore, in asymptomatic low- risk surgical patients with severe carotid stenosis, comparison of stroke, death, and myocardial infarction rates within 30 days, at 1- and 5-years following CAS with emboli protection device or CEA revealed non-significant differences (11). A recent meta-analysis of real-world practices of both CAS and SEA concluded non-significant differences of the 30-day neurologic events (CEA: 2.1% and CAS: 2.6%) (12).

In comparison to our findings, earlier studies reported less favourable outcomes in patients managed with CAS. A randomized clinical trial that evaluated outcomes of CEA and angioplasty in patients with symptomatic carotid stenosis of at least 60% revealed significantly lower rates of 30-days incidence of stroke or death after CEA (1.5%) than after stenting 3.4% (13). As well, within 30 days, ischemic stroke rates were 6.84% with and 6.34% in a randomized clinical trial that evaluated the outcomes of stent protected angioplasty versus CEA, respectively in symptomatic patients with carotid stenosis (14). The observed poorer outcomes after CAS in the former studies might be attributed to the lower use of emboli protection devices by their investigators. It has been reported that the use a device to capture and remove emboli with CAS was associated with lower incidence of stroke (12%) compared to CAS alone (20.1%) (15).

Another study compared outcomes of patients with symptomatic or asymptomatic carotid stenosis who were assigned into CAS or ECA. There was a significantly higher within 30 days incidence of stroke in the CAS group than the CEA group (4.1% versus 2.3%,  $p=0.01$ ), while the 30-days periprocedural incidence of myocardial infarction was significantly higher in CEA than CAS (2.3% versus 1.1%,  $p=0.03$ ). However, after the 30 days periprocedural period, the incidence of stroke was similar between stenting and endarterectomy with no significant differences (2.0% and 2.4%, respectively;  $p=0.85$ ) (16).

The comparable stroke, myocardial infarction, or death rates in the current study supports CAS as a treatment option for symptomatic carotid stenosis. Prior guidelines recommended CAS in high-risk surgical patients older 75 years (17, 18). Though, Yoshida and Miyamoto (19) reported that each technique is associated with specific high-risk features. Patients with severe cardiac comorbidity are considered as high-risk for CEA, while plaque morphology and

complicated vessel anatomy can also influence the outcomes of CAS. Therefore, the strategy of an individualized treatment selection should be followed.

The maximum benefit from revascularization procedures is obtained within 2 weeks of the symptoms. Thereafter, the efficacy has a tendency to decline (20). Though, the study of Rantner et al. (21) has shown non-significant differences in the risk of recurrent stroke between early revascularization within 14 days, intermediate intervention within 14-30 days, or delayed revascularization after 30 days on the onset of symptoms (22). In this context, analysis of the pooled data from four randomized clinical trials that compared stenting with CEA for symptomatic carotid artery stenosis concluded that when the procedures were done early during the first week after the onset of symptoms, CAS was associated with a substantially higher periprocedural death or stroke risk than CEA (8.3% versus 1.3%).

The secondary endpoints in the current study involved cranial-nerve injury, restenosis, vessel maturation, intracranial haemorrhage, and local hematoma within 30 days after the procedures.

Concerning the incidence of cranial nerve injury, none of the patients in the CAS group developed cranial nerve injury, while two patients (11.8%) in the CEA group developed cranial nerve injury, with no significant difference ( $p=0.204$ ). In this regard, an earlier large randomized clinical trial enrolled 2502 patients with asymptomatic and symptomatic carotid stenosis revealed higher cranial nerve palsy during the periprocedural period after CEA than CAS (16). Furthe et al (23) reported that 5.5% of the patients who underwent CEA developed cranial nerve injury, that was disabling in only one patient. A meta-analysis of randomized clinical trials reported that CAS was associated with lower rates of periprocedural cranial nerve palsy than CEA (24).

In this study, the incidence of local hematoma within 30 days was lower in the CAS group (5.0%) than in the CEA group (29.4%), but it did not reach a significant level ( $p=0.075$ ). Neck haematoma is a well-known complication after carotid endarterectomy. Tamaki and Morita (25) identified preoperative clopidogrel therapy and the lack of protamine sulfate using after heparin as risk factors for haematoma after CEA.

Within 30 days restenosis was detected in four patients (20.0%) belonging to the CAS group and two patients (11.8%) in the CEA group, with no significant difference ( $p=0.667$ ). This is in line with Bonati et al, Dobson (10) who reported a comparable 5-year risk of carotid restenosis in both CAS and CEA with no



significant difference.

This study is limited by its retrospective design and the low number of enrolled patients, besides the relatively short follow-up period. However, it provides outcomes of real-world practices of both CAS and CEA among different centers in Egypt.

**Conclusions:** Data of the present study indicate no significant difference in the incidence of death, stroke, or myocardial infarction rates within 30 days and at 1-year follow-up among patients undergoing CAS or CEA. Furthermore, there were no significant differences between CAS and CEA procedures regarding the incidence rates of cranial nerve injury, local neck hematoma, or restenosis within 30 days of the procedures. Therefore, CAS could be considered an efficacious and safe alternative intervention for symptomatic carotid stenosis.

## References

1. Wijeratne T, Menon R, Sales C, Karimi L, Crewther S. Carotid artery stenosis and inflammatory biomarkers: the role of inflammation-induced immunological responses affecting the vascular systems. *Ann Transl Med.* 2020;8(19):1276.
2. Lv W, Zhang T, Zhao H, He S, Li B, Gao Y, et al. Diagnostic value of miR-186-5p for carotid artery stenosis and its predictive significance for future cerebral ischemic event. *Diagnostic pathology.* 2020;15(1):101-.
3. Gokaldas R, Singh M, Lal S, Benenstein RJ, Sahni R. Carotid stenosis: from diagnosis to management, where do we stand? *Curr Atheroscler Rep.* 2015;17(2):480.
4. Aboyans V, Ricco JB, Bartelink MEL, Björck M, Brodmann M, Cohnert T, et al. 2017 ESC Guidelines on the Diagnosis and Treatment of Peripheral Arterial Diseases, in collaboration with the European Society for Vascular Surgery (ESVS): Document covering atherosclerotic disease of extracranial carotid and vertebral, mesenteric, renal, upper and lower extremity arteries Endorsed by: the European Stroke Organization (ESO) The Task Force for the Diagnosis and Treatment of Peripheral Arterial Diseases of the European Society of Cardiology (ESC) and of the European Society for Vascular Surgery (ESVS). *Eur Heart J.* 2018;39(9):763-816.
5. Naylor AR, Ricco JB, de Borst GJ, Debus S, de Haro J, Halliday A, et al. Editor's Choice - Management of Atherosclerotic Carotid and Vertebral Artery Disease: 2017 Clinical Practice Guidelines of the European Society for Vascular Surgery (ESVS). *Eur J Vasc Endovasc Surg.* 2018;55(1):3-81.
6. Li Y, Yang JJ, Zhu SH, Xu B, Wang L. Long-term efficacy and safety of carotid artery stenting versus endarterectomy: A meta-analysis of randomized controlled trials. *PLoS One.* 2017;12(7):e0180804.
7. Brott T, Adams HP, Jr., Olinger CP, Marler JR, Barsan WG, Biller J, et al. Measurements of acute cerebral infarction: a clinical examination scale. *Stroke.* 1989;20(7):864-70.
8. Meschia JF, Brott TG, Chukwudelunzu FE, Hardy J, Brown RD, Jr., Meissner I, et al. Verifying the stroke-free phenotype by structured telephone interview. *Stroke.* 2000;31(5):1076-80.
9. Taş MH, Simşek Z, Colak A, Koza Y, Demir P, Demir R, et al.

Comparison of carotid artery stenting and carotid endarterectomy in patients with symptomatic carotid artery stenosis: a single center study. *Adv Ther.* 2013;30(9):845-53.

10. Bonati LH, Dobson J, Featherstone RL, Ederle J, van der Worp HB, de Borst GJ, et al. Long-term outcomes after stenting versus endarterectomy for treatment of symptomatic carotid stenosis: the International Carotid Stenting Study (ICSS) randomised trial. *Lancet.* 2015;385(9967):529-38.

11. Rosenfield K, Matsumura JS, Chaturvedi S, Riles T, Ansel GM, Metzger DC, et al. Randomized Trial of Stent versus Surgery for Asymptomatic Carotid Stenosis. *N Engl J Med.* 2016;374(11):1011-20.

12. Nana P, Kouvelos G, Brotis A, Spanos K, Dardiotis E, Matsagkas M, et al. Early Outcomes of Carotid Revascularization in Retrospective Case Series. *J Clin Med.* 2021;10(5).

13. Mas JL, Chatellier G, Beyssen B, Branchereau A, Moulin T, Becquemin JP, et al. Endarterectomy versus stenting in patients with symptomatic severe carotid stenosis. *N Engl J Med.* 2006;355(16):1660-71.

14. Ringleb PA, Allenberg J, Brückmann H, Eckstein HH, Fraedrich G, Hartmann M, et al. 30 day results from the SPACE trial of stent-protected angioplasty versus carotid endarterectomy in symptomatic patients: a randomised non-inferiority trial. *Lancet.* 2006;368(9543):1239-47.

15. Yadav JS, Wholey MH, Kuntz RE, Fayad P, Katzen BT, Mishkel GJ, et al. Protected carotid-artery stenting versus endarterectomy in high-risk patients. *N Engl J Med.* 2004;351(15):1493-501.

16. Brott TG, Hobson RW, 2nd, Howard G, Roubin GS, Clark WM, Brooks W, et al. Stenting versus endarterectomy for treatment of carotid-artery stenosis. *N Engl J Med.* 2010;363(1):11-23.

17. Chaturvedi S, Bruno A, Feasby T, Holloway R, Benavente O, Cohen SN, et al. Carotid endarterectomy--an evidence-based review: report of the Therapeutics and Technology Assessment Subcommittee of the American Academy of Neurology. *Neurology.* 2005;65(6):794-801.

18. Goldstein LB, Bushnell CD, Adams RJ, Appel LJ, Braun LT, Chaturvedi S, et al. Guidelines for the primary prevention of stroke: a guideline for healthcare professionals from the American Heart Association/American Stroke Association. *Stroke.* 2011;42(2):517-84.

19. Yoshida K, Miyamoto S. Evidence for management of carotid artery stenosis. *Neurol Med Chir (Tokyo)*. 2015;55(3):230-40.
20. Rothwell PM, Eliasziw M, Gutnikov SA, Warlow CP, Barnett HJ. Endarterectomy for symptomatic carotid stenosis in relation to clinical subgroups and timing of surgery. *Lancet*. 2004;363(9413):915-24.
21. Rantner B, Kollerits B, Roubin GS, Ringleb PA, Jansen O, Howard G, et al. Early Endarterectomy Carries a Lower Procedural Risk Than Early Stenting in Patients With Symptomatic Stenosis of the Internal Carotid Artery: Results From 4 Randomized Controlled Trials. *Stroke*. 2017;48(6):1580-7.
22. **Batchelder A, Hunter J, Cairns V, Sandford R, Munshi A, Naylor AR. Dual Antiplatelet Therapy Prior to Expedited Carotid Surgery Reduces Recurrent Events Prior to Surgery without Significantly Increasing Peri-operative Bleeding Complications. *Eur J Vasc Endovasc Surg*. 2015;50(4):412-9.**
23. Doig D, Turner EL, Dobson J, Featherstone RL, de Borst GJ, Brown MM, et al. Incidence, impact, and predictors of cranial nerve palsy and haematoma following carotid endarterectomy in the international carotid stenting study. *Eur J Vasc Endovasc Surg*. 2014;48(5):498-504.
24. Sardar P, Chatterjee S, Aronow HD, Kundu A, Ramchand P, Mukherjee D, et al. Carotid Artery Stenting Versus Endarterectomy for Stroke Prevention: A Meta-Analysis of Clinical Trials. *J Am Coll Cardiol*. 2017;69(18):2266-75.
25. Tamaki T, Morita A. Neck haematoma after carotid endarterectomy: risks, rescue, and prevention. *Br J Neurosurg*. 2019;33(2):156-60.